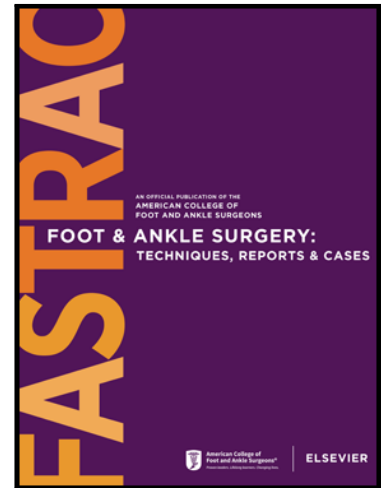


Journal Pre-proof

Long Term Functional Outcomes of Hallux Amputations at Various Anatomic Levels

Amish Dudeja DPM , Juan Ceja Solorio DPM ,
Kevin Buczkowski DPM , John Giurini DPM

PII: S2667-3967(23)00019-8
DOI: <https://doi.org/10.1016/j.fastrc.2023.100281>
Reference: FASTRC 100281



To appear in: *Foot & Ankle Surgery: Techniques, Reports & Cases*

Received date: 7 March 2023

Accepted date: 11 March 2023

Please cite this article as: Amish Dudeja DPM , Juan Ceja Solorio DPM , Kevin Buczkowski DPM , John Giurini DPM , Long Term Functional Outcomes of Hallux Amputations at Various Anatomic Levels, *Foot & Ankle Surgery: Techniques, Reports & Cases* (2023), doi: <https://doi.org/10.1016/j.fastrc.2023.100281>

This is a PDF file of an article that has undergone enhancements after acceptance, such as the addition of a cover page and metadata, and formatting for readability, but it is not yet the definitive version of record. This version will undergo additional copyediting, typesetting and review before it is published in its final form, but we are providing this version to give early visibility of the article. Please note that, during the production process, errors may be discovered which could affect the content, and all legal disclaimers that apply to the journal pertain.

Title: Long Term Functional Outcomes of Hallux Amputations at Various Anatomic Levels

Authors:

Amish K. Dudeja, DPM, AACFAS

Village Podiatry Centers, LLC.
120 Vann St. Ste. 100, Marietta, GA 30060
akdudeja23@gmail.com

Juan Ceja Solorio, DPM

Beth Israel Deaconess Medical Center
330 Brookline Ave, Boston, MA 02215
jcejadol@bidmc.harvard.edu

Kevin Buczkowski, DPM

Beth Israel Deaconess Medical Center
330 Brookline Ave, Boston, MA 02215
kbuczkow@bidmc.harvard.edu

John Giurini, DPM, FACFAS

Beth Israel Deaconess Medical Center
330 Brookline Ave, Boston, MA 02215
jgiurini@bidmc.harvard.edu

Corresponding Author:

Amish K. Dudeja, DPM, AACFAS

Village Podiatry Centers, LLC.
120 Vann St. Ste. 100, Marietta, GA 30060
akdudeja23@gmail.com

Format: Scientific

Length of Follow Up: Minimum 2 year follow up

Level of Evidence: III

Classification: Diabetic Foot

Purpose: Hallux amputations have long been used for treatment of hallux osteomyelitis as a result of ulcerations at various levels of the hallux. The aim of this study is to expand on a previously presented poster and to assess the long-term functional outcomes in patients with various levels of hallux amputations and determine whether there is an ideal anatomic level that will limit the amount of post-operative complications.

Methodology and Procedure: A retrospective review of 148 feet with hallux amputations performed at various levels from 7/1/2013 to 7/16/2020 was performed. Two years minimum follow up was required for inclusion in the study. Re-ulceration, further amputation, healing of index procedure, and revascularization status were evaluated. Statistical analysis utilizing chi square analysis was performed to calculate p values where <0.05 was statistically significant.

Results: A tendency for amputations performed at the level of the head of the proximal phalanx (67%) or at the metatarsophalangeal joint (52%) to have less re-ulceration rates.

Analysis and Discussion: Although partial hallux amputations have historically been considered more successful than full hallux amputations, our study shows that there is no statistically significant difference between levels of hallux amputations, particularly when looking at re-ulceration rates.

Disclosures: None