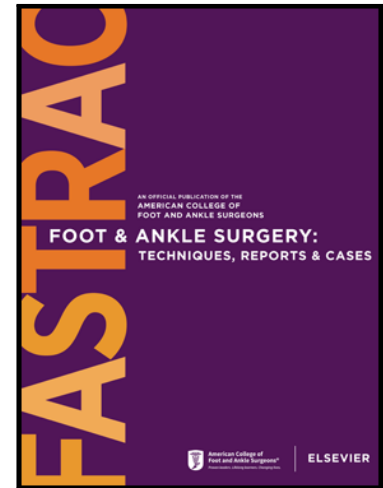


Journal Pre-proof

Short-Term Results of a Hybrid Total Ankle Arthroplasty Combining a Stemmed Intramedullary Tibial Component with Chamfer-Cut Talar Dome

Samantha A. Miner DPM, AACFAS , Philip Basile DPM, FACFAS ,
Monique Rodriguez DPM , Israel Bowers DPM ,
Keith Crenshaw DPM, MS

PII: S2667-3967(23)00018-6
DOI: <https://doi.org/10.1016/j.fastrc.2023.100280>
Reference: FASTRC 100280



To appear in: *Foot & Ankle Surgery: Techniques, Reports & Cases*

Received date: 4 March 2023
Accepted date: 6 March 2023

Please cite this article as: Samantha A. Miner DPM, AACFAS , Philip Basile DPM, FACFAS , Monique Rodriguez DPM , Israel Bowers DPM , Keith Crenshaw DPM, MS , Short-Term Results of a Hybrid Total Ankle Arthroplasty Combining a Stemmed Intramedullary Tibial Component with Chamfer-Cut Talar Dome, *Foot & Ankle Surgery: Techniques, Reports & Cases* (2023), doi: <https://doi.org/10.1016/j.fastrc.2023.100280>

This is a PDF file of an article that has undergone enhancements after acceptance, such as the addition of a cover page and metadata, and formatting for readability, but it is not yet the definitive version of record. This version will undergo additional copyediting, typesetting and review before it is published in its final form, but we are providing this version to give early visibility of the article. Please note that, during the production process, errors may be discovered which could affect the content, and all legal disclaimers that apply to the journal pertain.

ACFAS Annual Scientific Conference Poster Award Recipient

Title

Short-Term Results of a Hybrid Total Ankle Arthroplasty Combining a Stemmed Intramedullary Tibial Component with Chamfer-Cut Talar Dome

Authors

Samantha A. Miner, DPM, AACFAS^{1,*}; Philip Basile, DPM, FACFAS²; Monique Rodriguez, DPM³; Israel Bowers, DPM³; Keith Crenshaw, DPM, MS³

- 1 - Fellowship-Trained Foot & Ankle Surgeon, Upperline Health, Smyrna, GA, USA
 - 2 - Chief, Division of Podiatric Surgery, Department of Surgery, Mount Auburn Hospital, Cambridge MA, USA
 - 3 - Resident, Division of Podiatric Surgery, Department of Surgery, Mount Auburn Hospital, Cambridge, MA, USA
- * Primary and Corresponding author. 240-344-5956, dr.sam.miner@gmail.com, 3200 Highlands Parkway SE, Ste 100, Smyrna, GA, USA

ACFAS ASC 2023
POSTER ABSTRACT

Title: Short-Term Results of a Hybrid Total Ankle Arthroplasty Combining a Stemmed Intramedullary Tibial Component with Chamfer-Cut Talar Dome

Purpose: Total ankle arthroplasty (TAA) remains a viable alternative to ankle arthrodesis. The latest generation of TAA implant designs emphasize minimal bone resection and anatomic preservation. We have previously described our adapted technique combining an intramedullary tibial component with a minimal resection chamfer-cut talar component. The purpose of the present study is to report our short-term clinical outcomes with this hybrid technique.

Procedure: We performed a retrospective case series of consecutive patients undergoing primary TAA using this hybrid implant with a minimum of two-years follow up. Primary outcomes included the Visual Analog Pain Scale (VAS) and the American Orthopedic Foot and Ankle Society (AOFAS) Ankle-Hindfoot Scale. Secondary outcomes included rates of associated complications, reoperations, and revisions.

Results: Thirty-three consecutive patients (42% male, average age 59 years) met the inclusion criteria with an average follow up of 36 months. VAS improved from 7.1 preoperatively to 1.1 postoperatively ($p < 0.0001$). Similarly, AOFAS scores improved from 42.2 preoperatively to 90.7 postoperatively ($p < 0.0001$). Fifteen patients had a postoperative complication (45%), with 13 requiring a reoperation (39%), and 1 requiring a revision (3%).

Discussion: We found statistically significant improvement in patient-reported outcomes postoperatively with the majority of our complications being low-grade. At an average follow up of 3 years, implant survivorship was 97%. We demonstrate overall positive short-term clinical and radiographic outcomes of a novel hybrid TAA technique combining an intramedullary tibial component and a chamfer-cut talar component.

Declaration of interests

The authors declare that they have no known competing financial interests or personal relationships that could have appeared to influence the work reported in this paper.