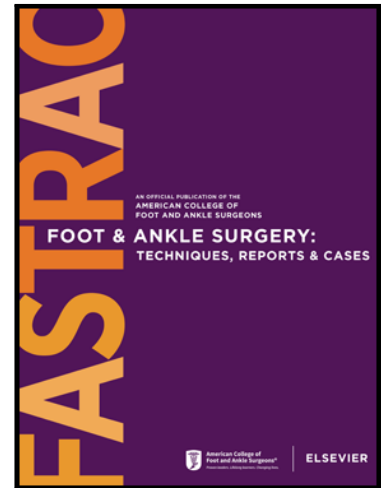


Journal Pre-proof

Peroneus Quartus, An Alternative for The Repair of Peroneus Brevis Tendon Tear

Anne Cossogue DPM Resident , Shuja Abbas DPM Resident ,
Lady Paula DeJesus DPM Attending , Eghosa Isa DPM Attending

PII: S2667-3967(23)00011-3
DOI: <https://doi.org/10.1016/j.fastrc.2023.100273>
Reference: FASTRC 100273



To appear in: *Foot & Ankle Surgery: Techniques, Reports & Cases*

Received date: 13 December 2022

Accepted date: 20 February 2023

Please cite this article as: Anne Cossogue DPM Resident , Shuja Abbas DPM Resident , Lady Paula DeJesus DPM Attending , Eghosa Isa DPM Attending , Peroneus Quartus, An Alternative for The Repair of Peroneus Brevis Tendon Tear, *Foot & Ankle Surgery: Techniques, Reports & Cases* (2023), doi: <https://doi.org/10.1016/j.fastrc.2023.100273>

This is a PDF file of an article that has undergone enhancements after acceptance, such as the addition of a cover page and metadata, and formatting for readability, but it is not yet the definitive version of record. This version will undergo additional copyediting, typesetting and review before it is published in its final form, but we are providing this version to give early visibility of the article. Please note that, during the production process, errors may be discovered which could affect the content, and all legal disclaimers that apply to the journal pertain.

© 2023 Published by Elsevier Inc. on behalf of American College of Foot & Ankle Surgeons.
This is an open access article under the CC BY-NC-ND license
(<http://creativecommons.org/licenses/by-nc-nd/4.0/>)

Case Reports and Series

Peroneus Quartus, An Alternative for The Repair of Peroneus Brevis Tendon Tear

Anne Cossogue, DPM*

Resident

Yale New Haven Health/ Bridgeport Hospital

Shuja Abbas, DPM

Resident

Yale New Haven Health/ Bridgeport Hospital

Lady Paula DeJesus, DPM

Attending

Yale New Haven Health/ Greenwich Hospital

Eghosa Isa, DPM

Attending

Kaiser Permanente, Sacramento Medical Center

*Corresponding author

Abstracts: The peroneus quartus is an accessory muscle of the lateral compartment of the leg which can be source of lateral ankle pathologies. When encountered during surgical interventions, the tendon can be used as graft for tendon repair. In this case report, the PQ was used for the repair of peroneus brevis tendon tear in three patients with satisfactory results.

Keywords: Peroneus Quartus, Magnetic Resonance Imaging, Anterior Talofibular Ligament, Peroneus Brevis

Introduction

First described by Otto in 1816, the peroneus quartus (PQ) is considered an accessory muscle of the lateral leg compartment with an incidence ranging from 6.6% to 23% in the general population^(1, 2). The most common origin of the PQ is the peroneus brevis muscle; however, its insertions vary from the lateral aspect of the calcaneus, the cuboid, and the base of the fifth metatarsal^(1,3,5). The muscle holds different origins and insertions hence its multiple names such as peroneus accessorius, peroneus calcaneus externus muscle, peroneocuboideus, and long peroneal tendon^(2, 4). The presence of the tendon is asymptomatic in most patients; nevertheless, it can be the cause of lateral ankle pain, subluxation of the peroneal tendons, peroneal tendon tear, edema, and retromalleolar pain⁽²⁾. The accessory muscle can often be identified as an incidental finding on ultrasound or magnetic resonance imaging (MRI) especially on the axial view running posteromedial or medial to the peroneus brevis tendon with a fat layer separation^(11, 12, 16). The PQ is not always observed on imaging, but is subsequently noted intra-operatively⁽¹⁵⁾. When encountered and identified intra-operatively in the surgical treatment of lateral ankle pathologies, the PQ can be excised and used in the repair of peroneal tendon retinaculum^(4,11,13,15). In the literature, the use of the PQ tendon for the repair of peroneus brevis tendon tears is limited. This case report presents three patients with lateral ankle pain and peroneus brevis tendon pathology based on clinical exams and MRI studies. Coincidentally, a PQ tendon was identified intra-operatively in all three patients and used as an autograft for the repair of the peroneus brevis longitudinal tendon tear with satisfactory outcomes.

Materials and Method

Three patients were considered from 2015 to 2017. The PQ tendon was identified in the lateral ankle in all three patients intra-operatively by the same surgeon who performed the procedures.

A 49 y/o female presented with a painful right ankle lasting 20 years after sustaining an ankle fracture. The musculoskeletal exam revealed tenderness to the right styloid process and stiffness to the anterior right ankle upon plantarflexion. There was pain on palpation to the peroneal tendon from the posterior fibular to the proximal to the base of the 5th metatarsal. The MRI showed right ankle joint effusion, a partial tear anterior talofibular ligament (ATFL), an OS trigonum, peroneal brevis split tendon tear, and mild degenerative changes involving the navicular.

A 23 y/o female presented with right ankle pain after a twisting mechanism while playing football. Physical exam demonstrated pain on palpation of the right ATFL, peroneal tendons, sinus tarsi and pain with subtalar joint inversion. The MRI revealed microtrabecular injury of the medial talar head and neck, mild peroneus longus tendinosis, a peroneal brevis tear, an accessory peroneus quartus muscle, and small ankle and posterior subtalar joint effusions.

Finally, a 37 y/o male patient presented with increasing right ankle pain over a period of 2 weeks after shopping all day with no acute trauma. Patient was a former dancer with a history of prior right ankle sprains. Physical exam revealed pain on palpation at the peroneal tendons & right ATFL and swelling of the ankle joint. Patient was also unable to do heel raises without pain.

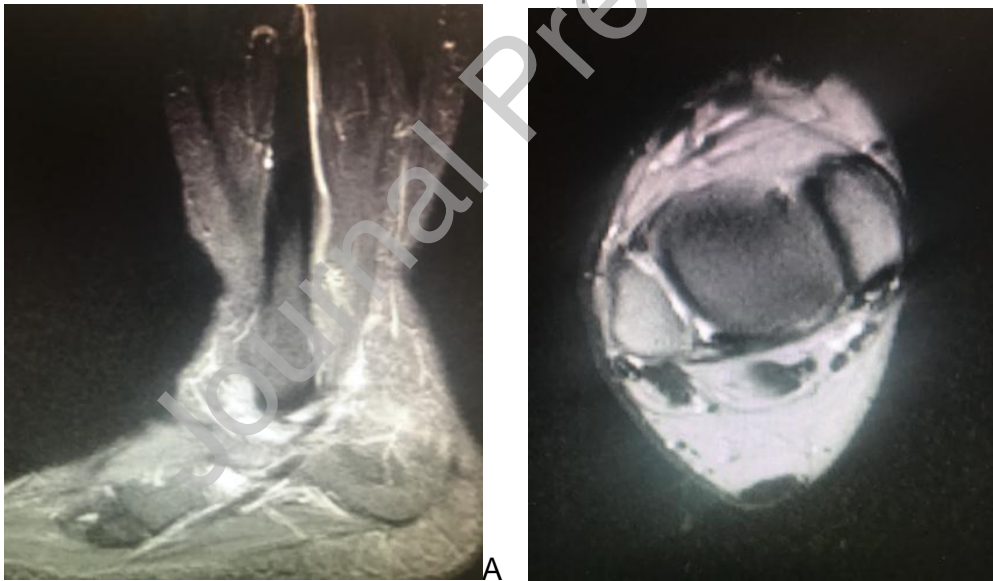


Figure 1. Sagittal and axial views of T-2 MRI of case 1. Increased intensity along the peroneus brevis tendon with tendonitis.

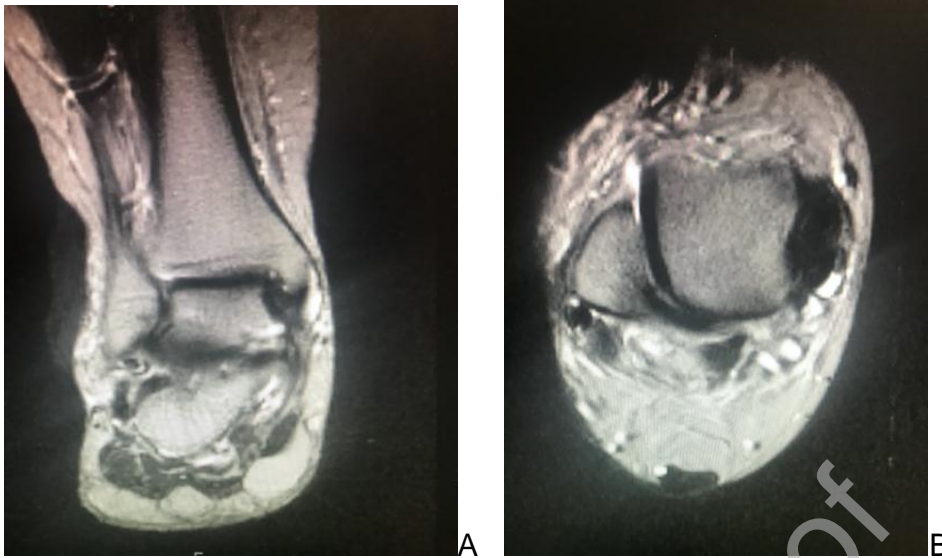


Figure 2. Coronal view of T-2 MRI of the ankle of case 2 A. Axial view of T-2 MRI of the ankle of case 3

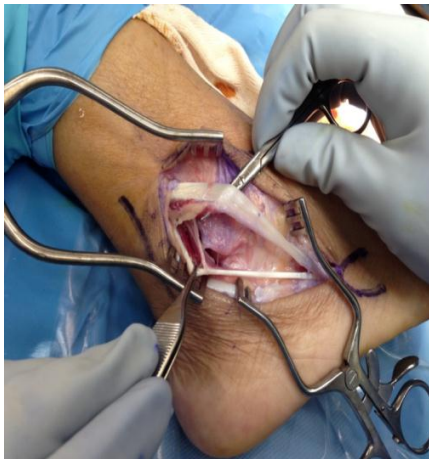
Surgical technique

The dissection and repair of the peroneus brevis was the same for all three cases. A curvilinear incision was placed along the peroneal tendons. Anatomical dissection was performed down to the peroneal tendons; the peroneus brevis was noted to have a longitudinal split tear. A low lying muscle belly of the peroneus brevis was noted distal to the lateral malleolus in one of the cases. The PQ arose from the peroneus brevis at the distal tip of the fibula or at the musculotendinous junction of the peroneus brevis in all three patients. The PQ was resected from its origin and used to augment the peroneus brevis tendon. The peroneus brevis tendon was tubularized using 2-0 Prolene in a running buried knot or running interlocking suture fashion with the PQ tendon centrally placed in the peroneus brevis tendon.

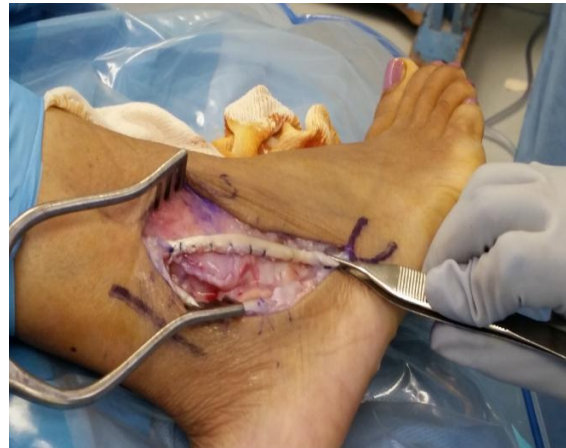Amniotic graft was then applied to the peroneal tendon for augmentation and to decrease the occurrence of soft tissue adhesions.

Adjunct procedures included resection of the os trigonum, lateral ankle ligament repair, arthroscopy of the ankle joint and cyst removal when necessary. Anatomic layered closure was performed and a bivalve fiberglass cast was applied upon completion.

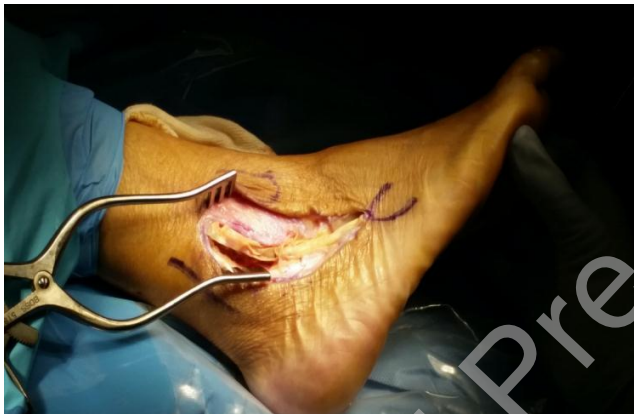Case 1



A.



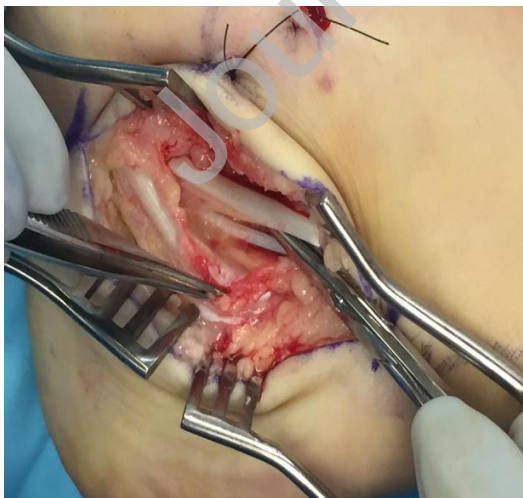B.



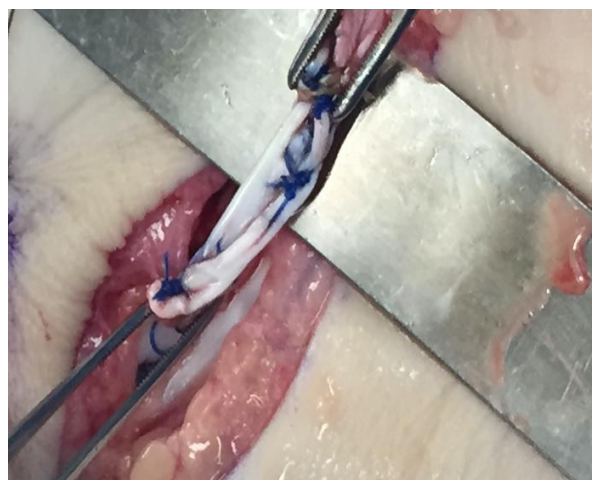
C.

Figure 3. Peroneus quartus tendon retracted with a forceps and flattened peroneus brevis tendon over the hemostat (A). Tubularized peroneus brevis tendon with augmentation with peroneus quartus with 2-0 prolene (B). Allograft over the tubularized peroneus brevis tendon repair (C).

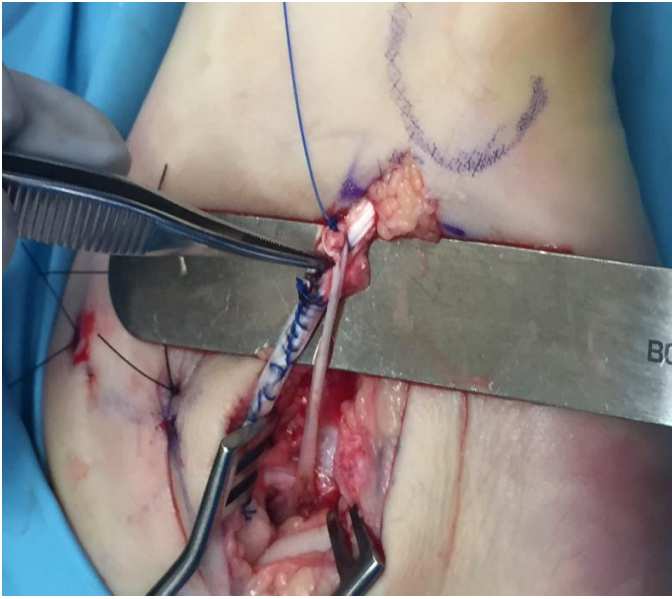
Case 2



A.



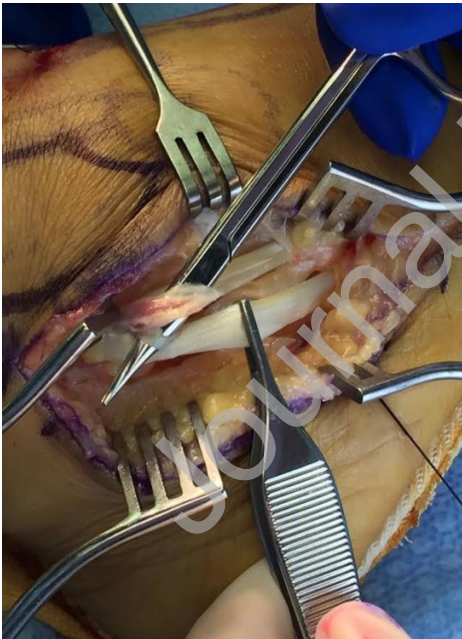B.



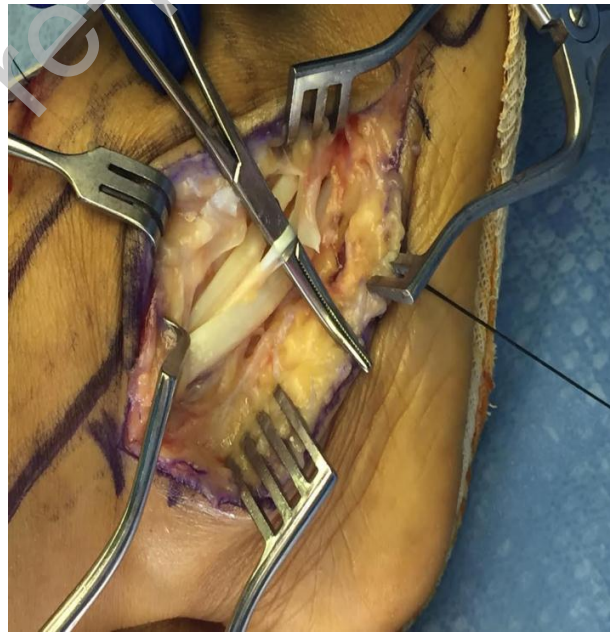
C.

Figure 4. Peroneus quartus tendon under the hemostat (A). Augmentation of peroneus brevis tendon with peroneus quartus tendon (B). Tubularized peroneus brevis tendon with peroneus quartus with 2-0 prolene(C).

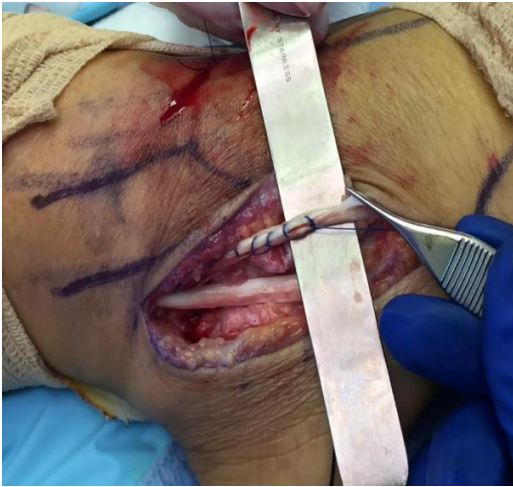Case 3



A.



B.



C.

Figure 5. Peroneus quartus is identified with the tenotomy scissors (A) and with the hemostat (B). Tubularized peroneus brevis with PQ with 2-0 prolene over the malleolus (C).

Results

Three patients presented with peroneus brevis tendinopathy based on history, physical exam, and MRI. All three patients underwent peroneus brevis tendon repair. PQ was identified in all three cases intra-operatively and used as graft for the augmentation of peroneus brevis repair. The patients were non weight bearing in a short leg cast for four weeks followed by partial weight bearing or weight bearing as tolerated in a walking boot for an additional four weeks. All three patients returned to their previous activities with minimal to no pain. Adjunct post op management included physical therapy and orthotics.

Discussion

The peroneus quartus is an accessory tendon of the lateral leg compartment that is encountered incidentally. Due to its location and various insertions, it can be a source of pain, discomfort, subluxation, and tear of the peroneus brevis tendon with increased pressure in the lateral retromalleolar area of the ankle. In this case review, we presented three patients with ankle pain with or without acute traumatic incidents or precipitating injury involving the foot and ankle. These injuries may develop from inversion sprain, subluxation of the peroneal tendons, instability of the lateral ankle ligaments, ligamentous laxity^(6,9). Imaging modalities in the diagnosis of these injuries are ultrasounds and MRIs. According to a review of MRIs conducted on 97 patients, Park et al. concluded that MRI has 44% sensitivity of detecting tears in the peroneus brevis and a 99% specificity^(7,8). Clinical presentation, physical exams, and advanced imaging of all three patients supported peroneal tendon injuries with or without concomitant ankle ligaments tear and other soft tissue pathologies. MRIs were obtained for all three patients and the PQ was not identified in one of the patients and subsequently encountered intra-operatively. The surgical repair of the PB tendon can be done through direct repair through tubularization, tendon transfer, or augmentation with either allograft or autograft^(13,14,17). All three patients underwent secondary repair of the peroneus brevis tendon with the PQ as augmentation. On follow up evaluation, all three patients reported alleviation of pain and lateral ankle symptoms with return to their

previous activities. No decrease in strength or alteration of gait was noted following resection of the PQ and its use as graft augmentation for the surgical repair of the peroneus brevis tendon.

Use of an autograft or allograft can be utilized for augmentation during a peroneal brevis repair. One must be aware that the use of autograft can lead to additional pain and potential iatrogenic injury to the donor site ⁽¹⁰⁾. However, we presented the use of PQ as an adjunct procedure for augmentation of peroneal brevis tendon repair with no complications.

Conclusion

The use of allograft, autograft, or tendon transfer is commonly employed in the repair of peroneal tendon tear. In this case report, PQ was used to repair peroneus brevis tendon tear in three cases. All three patients returned to their activities of daily living with minimal to no pain. The PQ can be used for the augmentation of peroneal tendon repair.

Informed Patient Consent

Complete informed consent was obtained from the patient for the publication of this study and accompanying images

Declaration of Competing Interest

The authors declare that they have no known competing financial interests or personal relationships that could have appeared to influence the work reported in this paper.

References

1. Zammit, J., and Singh, D. The Peroneus Quartus Muscle. Anatomy and Clinical Relevance. *The Journal of Bone & Joint Surgery* 2003; 85-B:1134-7.
2. Habashy, A., Cook, B., Sumarriva, G., Treuting, R. 2017. Peroneus Quartus Muscle. *The American Journal of orthopedics* 2017; E419-22.
3. Bilgili, M.G., Kaynak, G., Botanhoglu, H., Bararan, S.H., Ercin, E., Baca, E., Uzun, I., Peroneus Quartus: Prevalence and Clinical Importance. *Archives of orthopedic and trauma surgery* 2014.
4. Chinzei, N., Kanzaki, N., Takakura, Y., Takakura, Y., Toda, A., Fujishiro, T., Hayashi, S., Hashimoto, S., Kuroda, R., Kurosaka, M. Surgical Management of Peroneus Quartus Muscle for Bilateral Ankle Pain. *Journal of the American Podiatric Association* 2015; 105 (1): 85-91.
5. Molini, L., Bianchi, S. US of Peroneal Tendon Tear. *Journal of Ultrasound* 2014; 17:125-134.
6. Dombeck, M.F., Lamm, B.M., Saltrick, K., Mendicino, R., Catanzariti, A.R. Peroneal Tendon Tears, A Retrospective Review. *Journal of foot and ankle surgery* 2003; 42 (5): 250- 258.
7. Park, H.J., Lee, S.Y., Park, N.H., Rho, M.H., Chung, E.C., Kwag, H.J. Accuracy of MRI findings in characterizing Peroneal tendon disorders in comparison with surgery. *Acta Radiologica* 2012; 53: 795-801

8. O'Neil, J.T., Pedowitz, D.I., Kerbel, Y.E., Coddling, J.L., Zoga, A.C., Raikin, S.M., Peroneal Tendon Abnormalities on Routine Magnetic Resonance of the Foot and Ankle. *Foot and ankle international*. 2016.
9. Bahad, S.R., Kane, J.M. Peroneal Tendon pathology: treatment and reconstruction of peroneal tendon tears instability. *The orthopedic clinic of North America* 2020.
10. Nishikawa, D.R.C., Duarte, F.A., Saito, G.H., Netto, C.C., Monteiro, A.C., Prado, M.P., Grava de Sousa, I.F. Reconstruction of Peroneus Brevis tendon tears with semitendinosus tendon autograft. *Case Reports in Orthopedics* 2019.
11. Chepuri, N.B., Jacobson, J.A., Fessel, D.P., Hayes, C.W. Sonographic appearance of the Peroneus Quartus Muscle: Correlation with MR Imaging Appearance in Seven Patients. *Radiology* 2001; 218: 415- 419
12. Flor-de-Lima, B., Castro, M., Costa, A.S., Brito, N., Madureira, A.J. Magnetic Resonance Imaging of Common and Uncommon Peroneal Tendons Disorders. *Acta Radiologica* 2022; 34 (1): 9-16.
13. Mook, W. R., Parekh, S. G., Nunley, J.A. Allograft Reconstruction of Peroneal Tendons: Operative Techniques and Clinical Outcomes. *American orthopedics Foot and Ankle Society* 2013.
14. Hanselman, A, and Easley, M. Peroneal Tendon tear: when to use an allograft. *Techniques in Foot & Ankle Surgery* 2019; 18 (2).
15. Boomsma, S.E. Comparison of MRI and Operative Findings in Peroneal Tendon Disorders in a Military Population. *Foot and Ankle Orthopedics* 2016; 1 (1).
16. Wang, X.T., Rosenber, Z.S., Mechlin, M.B., Schweitzer, M.E. Normal Variants and Diseases of Peroneal Tendons and Superior Peroneal Retinaculum: MR Imaging Features. *RadioGraphics* 2005; 25: 587- 602
17. Trache, T., Camenzind, R.S., Bachmann, E., Viehofer, A., Jud, L., Wirth, S., Imhoff, F.B. A Biomechanical Analysis of Peroneus Brevis Split Lesion Repair and Partial Resection. *Foot & Ankle International* 2022; 43 (5) 710-716.