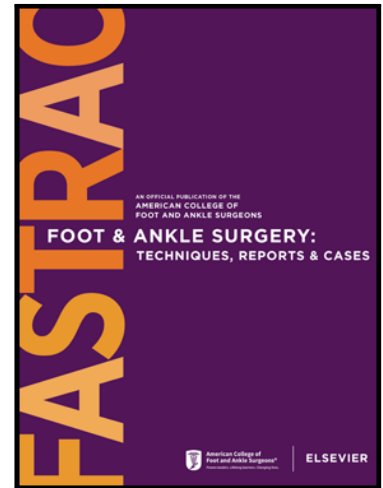


Journal Pre-proof

WITHDRAWN: Isolated Traumatic Dislocation of the Cuboid. A Case Report

Stuart A Aitken MBChB MD(Edin) FRCSEd(Tr&Orth)

PII: S2667-3967(21)00133-6
DOI: <https://doi.org/10.1016/j.fastrc.2021.100132>
Reference: FASTRC 100132



To appear in: *Foot & Ankle Surgery: Techniques, Reports & Cases*

Received date: 6 April 2021
Accepted date: 24 December 2021

Please cite this article as: Stuart A Aitken MBChB MD(Edin) FRCSEd(Tr&Orth) , WITHDRAWN: Isolated Traumatic Dislocation of the Cuboid. A Case Report, *Foot & Ankle Surgery: Techniques, Reports & Cases* (2022), doi: <https://doi.org/10.1016/j.fastrc.2021.100132>

This is a PDF file of an article that has undergone enhancements after acceptance, such as the addition of a cover page and metadata, and formatting for readability, but it is not yet the definitive version of record. This version will undergo additional copyediting, typesetting and review before it is published in its final form, but we are providing this version to give early visibility of the article. Please note that, during the production process, errors may be discovered which could affect the content, and all legal disclaimers that apply to the journal pertain.

© 2021 Published by Elsevier Inc. on behalf of American College of Foot Ankle Surgeons.
This is an open access article under the CC BY-NC-ND license
(<http://creativecommons.org/licenses/by-nc-nd/4.0/>)

WITHDRAWN: Isolated Traumatic Dislocation of the Cuboid. A Case Report

Stuart A Aitken MBChB MD(Edin) FRCSEd(Tr&Orth)

MaineGeneral Orthopaedics

This article has been withdrawn at the request of the author(s) and editor. The Publisher apologizes for any inconvenience this may cause.

The full Elsevier Policy on Article Withdrawal can be found at <https://www.elsevier.com/about/our-business/policies/article-withdrawal>